

Journal of Current Trends in Women's Health & Complications

Research Article

Neodymium: Yag Laser in the Varicose Treatment

Aristides Arellano Huacuja MD.FICS*, Dr. Dafne Arellano Montalvo, Dr. Anja Arellano Montalvo¹

Dermatology Clinic and Aesthetic Surgery Puebla Puebla, Mexico

Abstract

In the year of 1998, we started with the treatment of vascular lesions that occur in both legs and face in skins type III, IV and V in greater numbers. The use of this equipment has allowed good results in reticular veins, telangiectasias lesions. Better results are in hemangiomas and nevus flameus, (Port Winne Stain) and Sturge Weber, Rosacea and Poikiloderma de Civatte as well.

Introduction

Veins are thin-confine, low-pressure conduits whose function is the return of blood from the periphery (lower extremities) to the heart. The mechanism that favors this return involves the presence of venous valves, the muscular action, through its contraction, the arterial pulsatility neighboring the deep veins and the respiratory physiology, by the alternation of the intrathoracic pressure, among other mechanisms [1]. The venous flow of the lower extremities has the characteristic of being centripetal (from the superficial to the deep veins) and as mentioned previously from the lower extremities to the heart.

EVC is usually caused by primary alterations of the venous wall or valves. These alterations can also be caused secondarily by the sequelae of deep vein thrombosis (DVT), which produce reflux, obstruction or both. Venous malformations are also a cause, although very rare, of EVC [2]. Chronic venous insufficiency (CVI) is a term that, according to current consensus, should be reserved for advanced CVA, in those cases in which edema, trophic skin disorders and ulcers occur.

The clinical history and physical examination alone do not always indicate the characteristics and extent of the problem, so diagnostic techniques have been developed to determine the anatomical and functional implication of the obstruction and reflux, as well as the dysfunction of the muscular pump [3,4].

Over the years, various laser light systems have been used in the treatment of vascular lesions. The laser is an apparatus that consists of active media, whether gaseous, liquid or solid enclosed within a resonant cavity, limited by a pair of parallel plane mirrors perfectly specular and other semi-transparent [5].

Einstein was the one who for the first time suggested the bases on the controlled manipulation of light waves in the year of 1917. It was not until 1960 when the first laser was built (Light amplification by stimulated emission of radiation), and one of its main applications was in the treatment of cutaneous vascular lesions [6,7]. Giving origin to the argon laser, created in 1960 by Maiman being a laser of continuous emission, with wavelengths between 488 and 514 nm.

Later, in the mid-1990s, the IPL (IPLS-Intense Pulsed LIGHT source) was used, which uses a high-energy flash lamp system with a spectrum of variable wavelengths, ranging from 515 to 1200 nm [8].

The most recent laser used in the treatment of blood vessels is the pulsed Nd: Yag of 1064 nm, which emits energy up to 150j / cm² [9]. This system is based on the deep penetration of these wavelengths in order to coagulate vessels of greater caliber (especially of the lower extremities); such as reticular varicose veins, essential and secondary telangiectasias, replacing sclerotherapy [10].

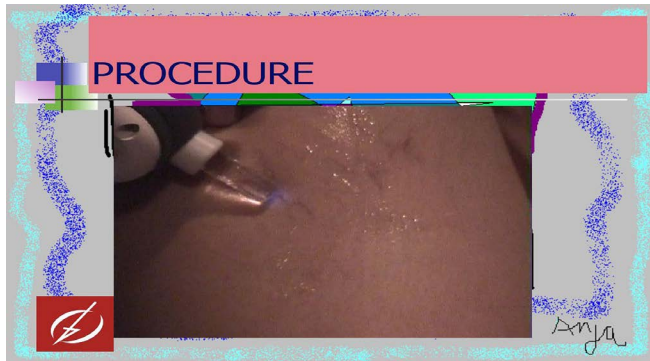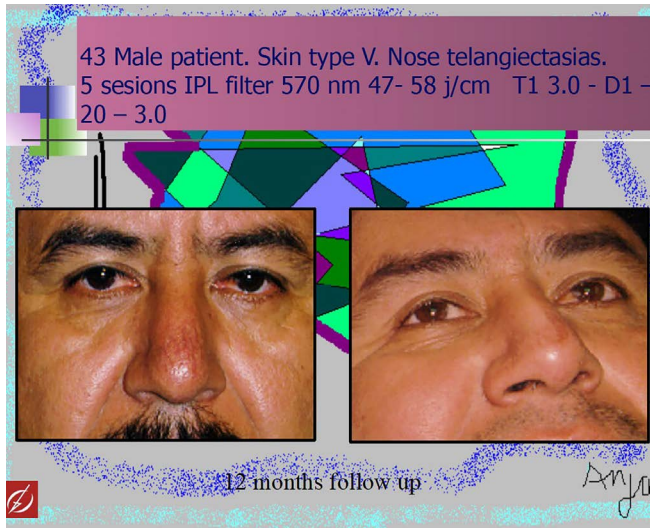
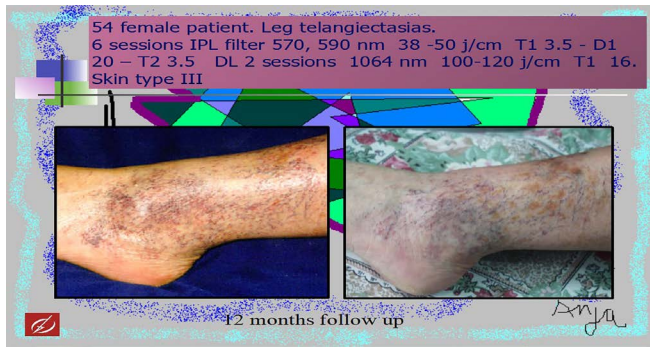*Corresponding Author:

Aristides Arellano-Huacuja MD,
Dermatology Clinic and Aesthetic Surgery Puebla. Puebla, 20 sur 2539
Col. Bella Vista. 72500 Mexico.
aristidesarella@yahoo.com.mx

Received Date: 04 Nov, 2022

Accepted Date: 14 Nov, 2022

Published Date: 06 Dec, 2022



The laser light is selectively absorbed by the chromophore (hemoglobin), generating heat by raising the temperature above the coagulation point, causing the reabsorption of all the vascular walls.

As it is to be supposed, the pathologies that involve the different kinds of veins are conditioned by the location and function of each of them, the network of deep veins, by controlling a high percentage of the blood return (approximately 80%), are associated commonly with venous insufficiency [11]. The perforating veins sometimes suffer injuries in their valvular structures, losing the unidirectional nature of their flow, so that the blood coming from the deep system flows back to the superficial veins, dilating them and making them varicose.

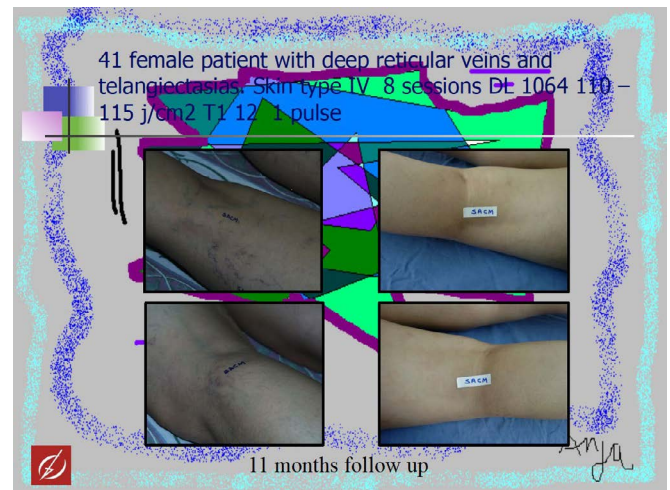
As is well known, the prevalence of venous pathology in our environment is extraordinarily high. A variety of factors contribute not only congenital, but also acquired such as multiple pregnancies, trauma, standing for a long time, etc. From this point of view, the suffering included in this category,

as well as many others that evidence a strong participation of educational and cultural factors [12].

Classification of the venous system:

- Superficial: composed of the internal saphenous and external saphenous veins and their tributaries.
- Deep: Located under the fascia, composed of the deep veins that accompany the arteries and receive their name. Responsible for 80-85% of venous return.
- Communicator: composed of veins that perforate the fascia and communicate the superficial and deep venous system. Being the direction of the flow from superficial to deep. (twenty)

The dilated and tortuous superficial veins usually have incompetent valves. Usually, they are a problem that involves the internal and external saphenous veins. The highest incidence occurs after age 20, three times more frequent in women 2.6% according to the Framingham study, due to the intervention of predisposing factors such as pregnancy, menopause and inheritance [13]. As well as sequelae of deep thrombophlebitis with venous recanalization. While in men only 1.9% of the population is affected.



Among the predisposing factors for CVI, we will mention the following as the most frequent:

- Genetics: Some studies show that the risk of developing varicose veins in children with both parents with varicose veins would reach up to 90%.
- Sex: predominance of female sex in 4: 1 proportion
- Age: greater frequency between 30 and 60 years.
- Weight: higher incidence in obese people.
- Pregnancy: more frequent in multiparous women. Pregnancy would favor the appearance of CVI through 3 mechanisms; the hormonal changes that take place during pregnancy that cause a decrease in venous tone, an increase in blood volume and an increase in intra-abdominal pressure that alters venous return.
- Race: a higher frequency of CV appearance has been described in Nordic and Central European countries than in Mediterranean countries. More frequent in white race very uncommon in black and Asian race.
- Diet and bowel habits: constipation favors the appearance

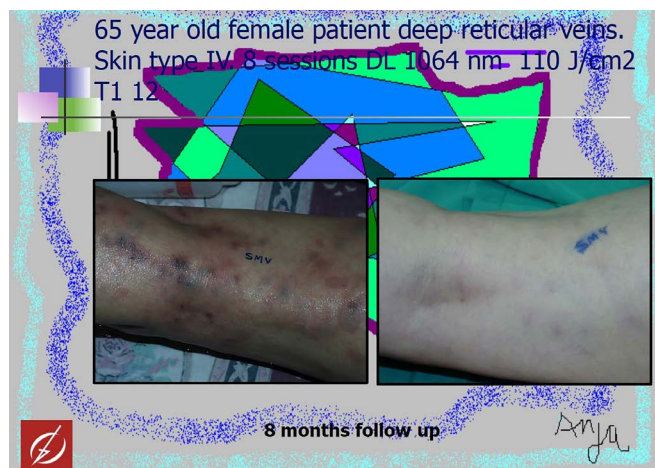of varicose veins due to an increase in intra-abdominal pressure.

- Work: it increases its incidence in standing jobs or in people who spend a lot of time sitting.
- Typ: the presence of thrombi in the venous confluence and valves activate a series of inflammatory phenomena that produce their fibrosis and subsequently their incompetence.

Objective

To evaluate the results obtained with the pulsed light IPL and the Neodymium Yag Laser in the treatment of venous insufficiency of lower limbs considering the decrease in the clinical picture that the patient may present, such as:

- Pain: type heaviness of legs of predominance vespertine. Due to distension of the vein wall and increased tissue tension secondary to venous hypertension.
- Itching: in sensitive or dry skin.
- Cramps.
- Edema: It is the increase of fluid in the interstitial space because of the increase in capillary venous pressure that leads to the leakage of fluid from the intravascular space. Clinically, it is translated as an increase in the volume of the leg that, when palpated, produces a positive foveal sign. It is usually one-sided and gets worse during the day.
- Varicose veins: the destruction, overreaching and disappearance of the vein treated with the Neodymium Yag laser and the IPL.
- Cutaneous alterations: such as hyperpigmentation.
- Eczema: erythema and scaling of the skin, initially affecting the inferior internal face of the leg to later progress and compromise the entire limb. In advanced stages and product of erythrocyte extravasation and hemosiderin accumulation in the dermis, brown coloration of the skin occurs.



- Lip dermatosclerosis: increased thickness of dermal and subdermal tissue. Clinically, other dermatitis is seen in the distal third of the legs, with hardening of the skin, which is attached to deep planes.
- White atrophy: stellate, smooth, ivory white plaques with a sclerotic consistency punctuated by telangiectasias and petechiae surrounded by a hyperpigmented halo. They are located mainly in the lower third of the legs and feet.
- Venus Ulcer is a solution of skin continuity, without tendency to spontaneous healing. They are in the peri malleolar regions, they are of variable size and depth, being

- able to affect the entire circumference of the leg and compromise up to the muscle. They are dirty bottom with fibrin and areas of granulation tissue.

Material and method

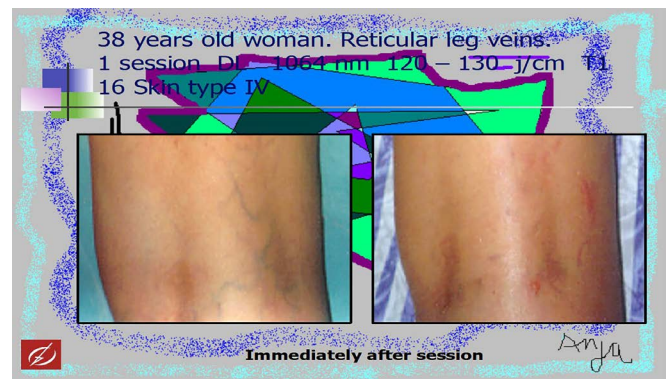
Between October 1998 and August 2017, 6509 patients with venous insufficiency of the lower limbs were treated, all women between the ages of 26 and 45 with the IPL system with phototypes of Fitzpatrick III to V, using the following filters 550 and 570, later in August of 1999 and September of 2017 the treatment with the Neodymium laser was continued having a female population of (90.00%) and (10.00%) males with ages ranging from 20 to 70 years [14-16].

All the cases presented veins (spider), telangiectasias, reticular and some with tortuous veins [17]. The parameters we used for telangiectasias were low power, for reticular we used 110j/cm² at a single pulse with a delay of 12 ms and for veins greater than 6mm we used 120 j/cm² double pulse and a delay of 7 ms.

The most recent laser used in the treatment of blood vessels is the ND YAG pulsating at a length of 1064 nm, which emits energy up to 150j / cm² [18,19].

This system is based on the deep penetration of these wave lengths in order to photo coagulate larger blood vessels (especially in the lower extremities), as reticulated varicose veins, essential and secondary telangiectasias, and, therefore, substituting for sclerotherapy.

The light of the laser is absorbed in a selective way by



chromophore (hemoglobin), generating heat over the point of coagulation and causing the re-absorption of the vascular walls. The laser can clear deeper veins up to 5 mm diameter as well as surface vessels [20].

There are sources combined with IPL and Nd: YAG laser technologies. Selective photo thermolysis broad spectrum IPL and Nd: laser penetrates the skin and is preferentially absorbed by vessels, pigment clusters or hair follicles, based on the chromophore tissue.

During treatment non-invasive laser energy is absorbed by hemoglobin, converted to heat energy. Immediately after treatment blood coagulates and vessel wall collapses. After treatment overtime vessel is reabsorbed and disappears [21].

Results

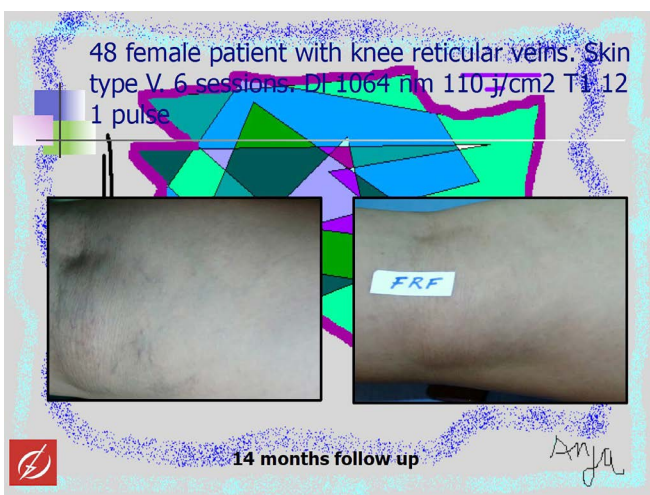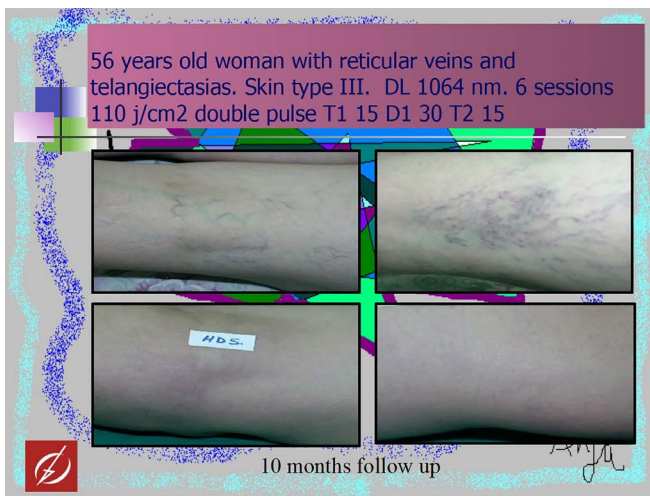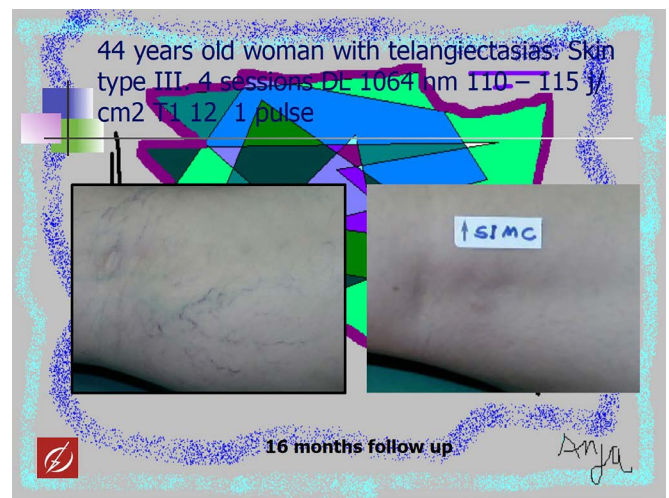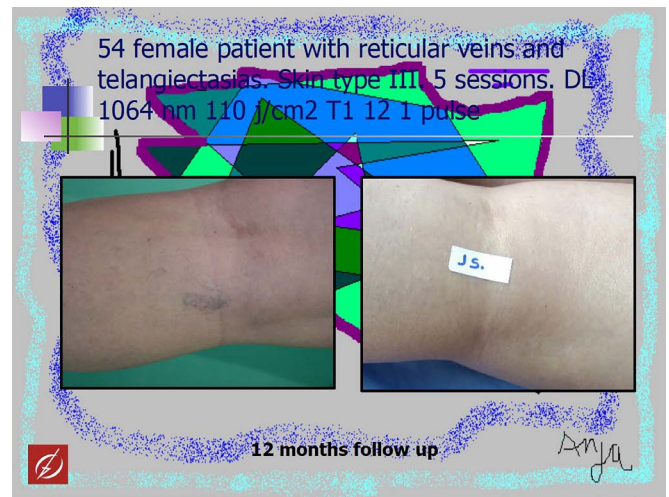The Laser-Tissue interaction depends on the wavelength and the characteristics of the tissue, pigment or chromophore, the latter being hemoglobin, water and melanin. When the light wave penetrated the tissue the degree of accumulated heat and the amount of time of this light wave will determine the action of the laser. If you consider the time calculated in seconds, you can calculate the energy (joules). The thermal effect of the laser

on a tissue depends on the heat emitted by it, which depends on the amount of energy and how long it lasts. Modern lasers have the peculiarity of emitting an effective long pulse wavelength, without affecting the surrounding tissues of the condition that one wishes to treat, such is the case of Nd, Yag.

With the IPL system we only obtained good results in telangiectasias, however with the Neodymium Laser the clinical improvement presented by the patients with venous insufficiency has been 80% to 85% on average, we have only had two cases of abandonment of treatment, for present pain when performing it. **Table 1.**

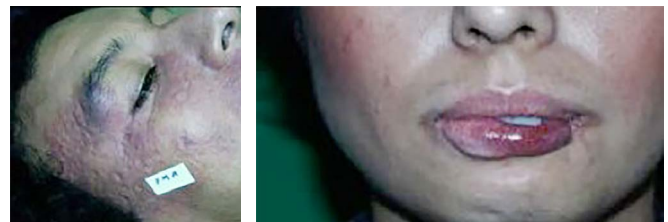Table 1.
Percentage of vein clearance after treatment.

TYPE OF INJURY	NO. OF PATIENTS	CLEARING %
RETICULAR VEINS	4235	90
TELANGIECTASIAS	1074	85
HEMANGIOMAS	747	82
POIKILODERMIA	453	87



Complications

The complications that have been presented to us after treatment are hyperpigmentation which has had a spontaneous resolution and without sequelae and the hypopigmentation that has remitted with the application of Puva therapy or phototherapy and exposure to the sun in a period of approximately 6 months. In few cases, there was a blister due to a 2nd degree burn on the treated skin. We also had cases with depression of the treated area.



These two light sources have proven over the years to be very safe and effective in the treatment of vascular conditions without producing hypertrophic scars and keloids such as the Argon laser among others [21].

Recommendations

We suggest that patients take the following self-care steps to help manage venous insufficiency:

- Do not sit or stand for long periods. Even moving the legs slightly helps to keep the blood flowing.
- Care for wounds if you have any open sores or infections.
- Lose weight if you are overweight.
- Exercise regularly.
- Patient can wear compression stockings to improve blood flow in the legs. Compression stockings gently squeeze the legs to move blood up.
- This helps prevent leg swelling and, to a lesser extent, blood clots.

Conclusions

The therapy used for the treatment of venous insufficiency of the lower limbs with the Neodymium Laser: Yag, is an outpatient treatment which does not need to be left alone to take care of the sun so as not to tan and to be able to perform the treatment, the improvement obtained in the first session has it was 30% on average and in the third session 70% improved the symptomatology presented in the legs such as pain, foot edema, numbness and temperature changes.

It is not necessary to perform surgery or compression treatment such as elastic stockings, elastic bandages, pneumatic compression. Pleotropic, hemorheological, sclerosing drugs, etc.

Considering that these technologies have already passed the testing period that any new technology deserves, lasers are a good method for the treatment of varicose veins, and angiomas. The telangiectasias and reticular varices obtaining results that approach 90%. In cases where patients do not want injectable treatments, or are anticoagulated, these techniques are ideal and highly recommended for patients.

When patients have become complicated and have angiogenesis or matting, there is no other effective treatment to date other than Intense Pulsed Light or IPL and the Laser Neodymium: Yag at 1064nm. When patients have associated spindle veins, the precise indication is the 980-diode laser, which by means of a simple canalization with a venous catheter 16 G is introduced and photocoagulates the vein, making it disappear immediately and with a post-operative almost non-existent [21].

Conflict of Interest: None

Source of Funding: None

References

1. Kienie A, Hibt R (1997) Optical parameters for laser treatment of leg telangiectasias. *Laser Med Surg* 20: 346-53.
2. Goldman MP, Eckhouse S (1996) Photo thermal sclerosis of leg veins. *Dermatol Surg* 22: 223-30.
3. Sonden A, Swenson B, Raoman N, et al. (2000) Laser induced shock wave endothelial cell injury. *Laser Med Surg* 26: 364-75.
4. Dover JS, Sadick NS, Goodman MP (1999) The role of laser and light sources in the treatment of the veins. *Dermatol Surg* 24: 328-36.
5. Reisfeld PL (2000) Blue in the skin. *J Am Acad Dermatol* 42: 597-605.
6. Adrian RM (1998) Treatment of leg telangiectasias using a long-pulse frequency-doubled neodymium: YAG laser at 532 nm. *Dermatol Surg* 24: 19-23.
7. Bernstein EL, Kornbluth S, Brown DB, Black J (1999) Treatment of spider veins using a 10-millisecond pulse duration frequency-doubled neodymium: YAG laser. *Dermatol Surg* 25: 316-21.
8. Massey RA, Katz BE (1999) Successful treatment of spider leg veins with a high-energy long pulse frequency doubled neodymium: YAG laser (HELPG). *Dermatol Surg* 25: 678-80.
9. Cisneros JL, Del Rio R, Palou J (1998) Sclerosis and the Nd: YAG Q-switched laser with multiples frequency of telangiectasias, reticular veins and residual pigmentation. *Dermatol Surg* 1119-23.
10. Goldman MD, Fitzpatrick RE (1990) Pulse-dye laser treatment of leg telangiectasias with and without simultaneous sclerotherapy. *J Dermatol Surg Oncol* 16:338-44.
11. West TB; Sister TS. Comparison of the long pulse dye (5590-595nm) and KTP (532 nm) laser in the treatment of facial and leg telangiectasias. *Dermatol Surg* 1998; 24:221-6.
12. Hohenleutner V, Wenig T, Wenig M, Baumier W, Landthaler M (1998) Leg telangiectasias treatment with a 1.5 ms pulse dye laser, ice cube cooling of the skin 595vs. 600 nm – preliminary results. *Lasers Med Surg* 23: 72-8.
13. Bernstein EF, Lee J, Lowery J, et al. (1998) Treatment of spider veins with the 595nm pulsed dye laser. *J Am Acad Dermatol* 39: 746-51.
14. Alora MB, Stern RS, Arnot KA, Dover JS (1999) Comparison of 595 nm long pulse (1-5 msec) and ultra-long pulse (4 msec) lasers in the treatment of leg veins. *Dermatol Surg* 25: 445-49.
15. Reichert D (1998) Evaluation of the long pulse dye lasers for the treatment of leg telangiectasias. *Dermatol Surg* 24: 737-40.
16. Hsia J, Lowery JA, Zelickson B (1997) Treatment of leg telangiectasias using a long-pulse dye laser at 595nm. *Lasers Med Surg* 20: 1-5.
17. Goodman MA, Martin DE, Fitzpatrick RE; Ruiz-Esparza J (1990) Pulse dye laser treatment of telangiectasias with and with and without sub therapeutic sclerotherapy. *J Am Acad Dermatol* 23: 23-30.
18. Green D (1998) Photo thermal removal of telangiectasias of the lower extremities with Photoderm VL Flash lamp as a new treatment possibility for vascular skin lesions. *Dermatol Surg* 24: 743-48.
19. Miguel Abbad C, Rial Horcajo R, Ballesteros Ortega Ma D, Garcia Madrid C *Guia practica clinica en enfermedad venosa crónica* 1-48.
20. Mege Navarrete M. *Insuficiencia venosa de extremidades inferiores* 1-17.
21. Simkin R, Bulloj R, Simkin CG (2006) *Laser en flebologia* 1-48.